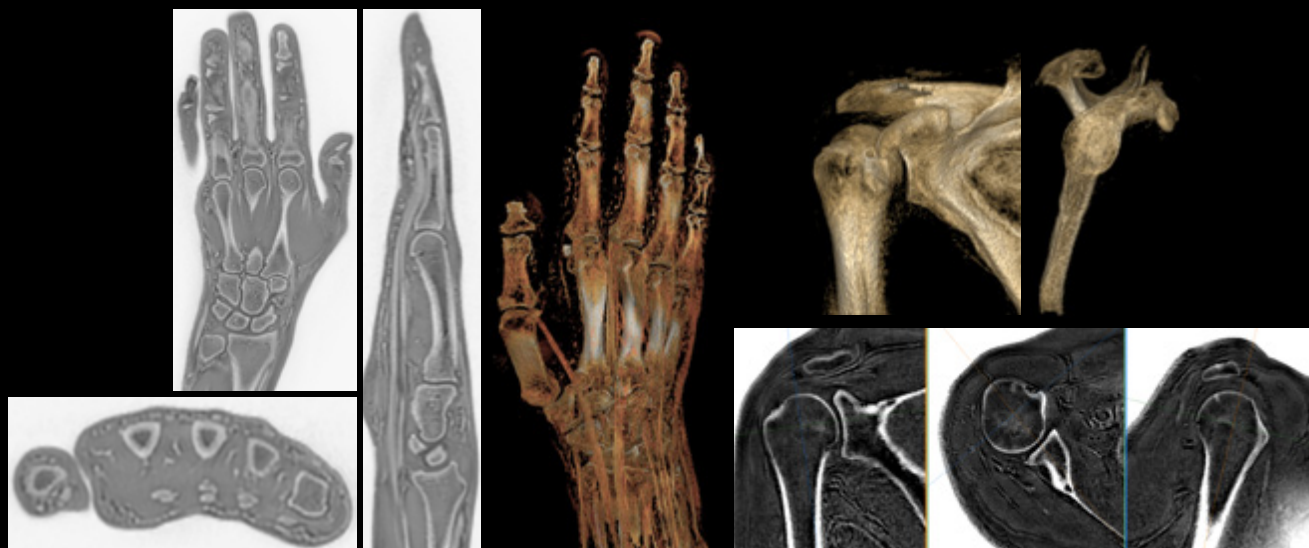



oZTEo for MR bone imaging

Delivering a one-stop shop for orthopedic imaging



Expand your MSK scanning capabilities with oZTEo

With this new application for imaging cortical bone surfaces, based on the radial Zero TE (ZTE) application, you can be a one-stop shop for bone imaging and add considerable clinical value to your orthopedic exams. oZTEo is inherently motion-insensitive and complements a conventional MR soft-tissue exam to deliver co-registered 3D isotropic imaging with familiar bright bone contrast.

In our experience, the routine use of ZTE has made it possible to highlight bone pathologies or the presence of calcifications. Our MR exams have become more efficient since they now combine the usual soft tissue differentiation of conventional MR with the almost CT-like appearance of ZTE.

Eric Lévêque, RT(R)(MR)
Clinique du Sport and IRM
Jardin des Plantes Paris, France

oZTEo at-a-glance

- Images bone morphology, calcification, ossification and fractures
- Complements the conventional MR soft tissue exam with perfect co-registration
- Provides 3D isotropic imaging using a radial ZTE acquisition, with inherent motion insensitivity
- Use with Volume Illumination for realistic 3D rendering
- Available for all anatomies
- Without ionizing radiation

THE HISTORICAL PROBLEM WITH MR

Thus far, MR imaging has been primarily a soft-tissue imaging modality where tissues such as ligaments, tendons, calcifications and cortical bone surfaces were assessed from the signal void in the image. Such tissues have extremely short T2 relaxation times, causing the MR signal to have decayed at the TE time of signal detection with conventional MR pulse sequences.

oZTEo for MR bone imaging

Recently, direct MR imaging of short T2 tissues has become possible with novel pulse sequences such as ZTE. GE presently uses ZTE as a means of Silent Scanning and has adapted it for MR bone imaging through the oZTEo commercial offering, which is available in the SIGNA™ Works AIR™ IQ Edition software release. oZTEo images show inverted contrast to enable sharp contrast between cortical bone and surrounding soft tissue, resembling a CT or x-ray. The acquisitions are relatively silent and insensitive to motion and can be acquired in a 3D isotropic manner, suitable for segmentation and volume rendering.

SIGNA™ MR system compatibility:

- Voyager 1.5T
- Artist & Artist Evo* 1.5T
- Pioneer 3.0T
- Hero* 3.0T
- Architect 3.0T
- Premier 3.0T
- 7.0T*

Is your orthopedic imaging practice ready for 3D printing?



oZTEo image data sets can be 3D rendered and saved as STL, VRML, 3MF, and OBJ file formats.

... the oZTEo sequence is used to increase the conspicuity of abnormal, soft tissue ossification that can help differentiate acute from chronic injuries, an important distinction in the competitive athlete who may have a long injury history.

Hollis Potter, MD

Hospital for Special Surgery, NY, NY

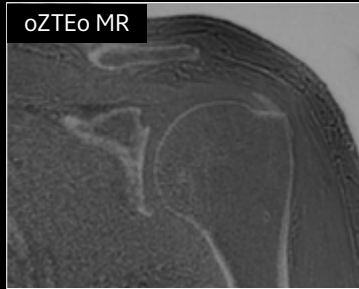
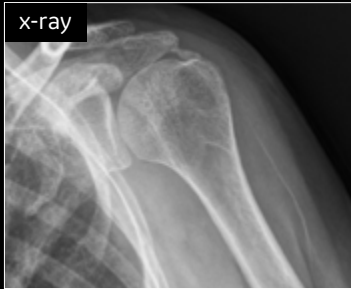
When oZTEo is included in an MR exam, cortical bone information is perfectly co-registered with the soft tissue series, making it a one-stop imaging shop for most routine MSK needs. oZTEo MR bone imaging provides a CT-like image contrast without ionizing radiation, making it an attractive alternative for pediatric and pregnant patients where ionizing radiation is a concern. In addition, it provides a welcome alternative when longitudinal CTs are required, particularly when low-dose CT systems are unavailable. We believe that MR bone imaging might also help imaging facilities prioritize their use of CT for more emergent cases. Finally, having both soft tissue assessment and bone imaging within the same exam can lessen the burden on the patient to attend two separate imaging modality appointments and may also lead to reduced healthcare costs.

Survey says...

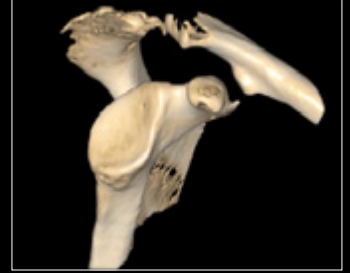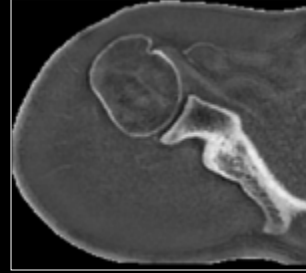
Based on a 2021 marketing survey including 65 radiologists, radiology directors and chiefs of radiology in five different countries.

- 92% of respondents think that oZTEo MR bone images could lead to a more confident differential diagnosis.
- 74% think offering oZTEo will increase their referral volume.
- 55% of respondents think oZTEo can benefit pediatric and pregnancy populations.
- 42% of respondents said they will add oZTEo to nearly half of their routine exams.
- Spine, shoulder and pediatrics are considered the key applications for oZTEo.

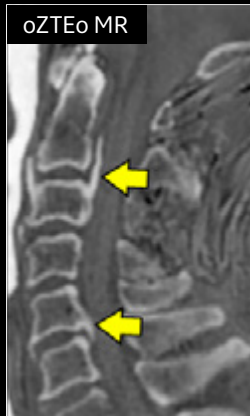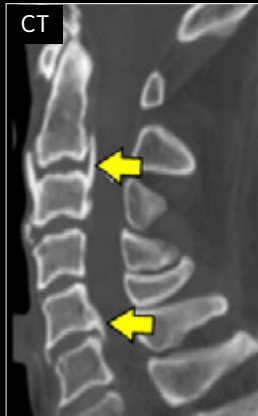Can your MR do this?



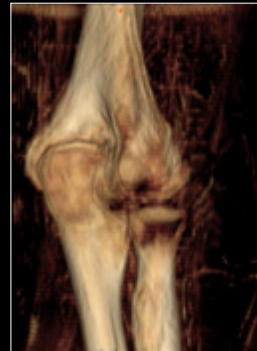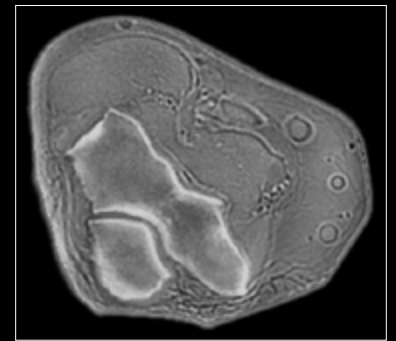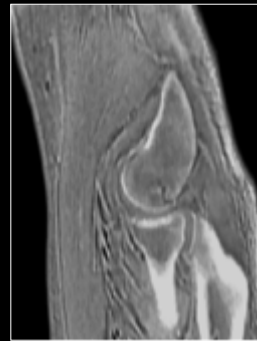
Calcific tendinitis in the shoulder



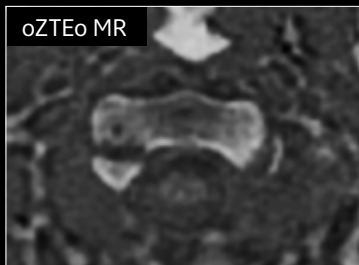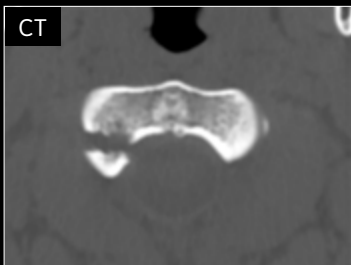
oZTEo shoulder
3D rendering with Volume Illumination
1.0 mm isotropic
3:33 min.



Ossification of the longitudinal ligament

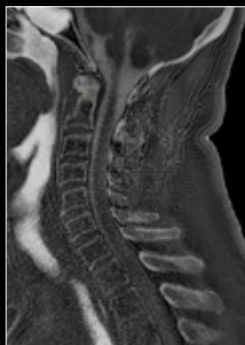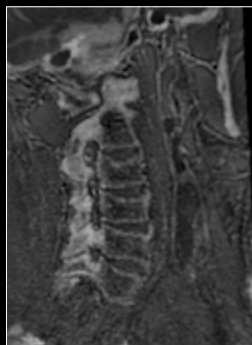


Elbow
0.9 x 0.9 x 1.7 mm
3:08 min.

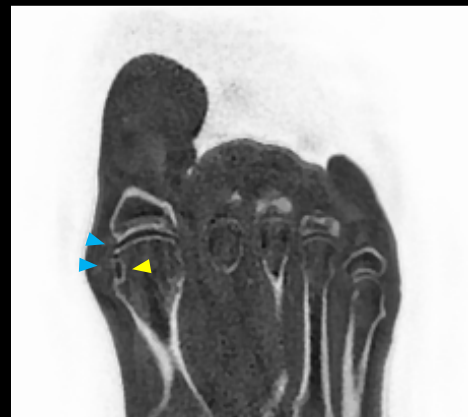

Cervical spine fracture

Tophaceous gout with erosion at the first metatarsophalangeal joint

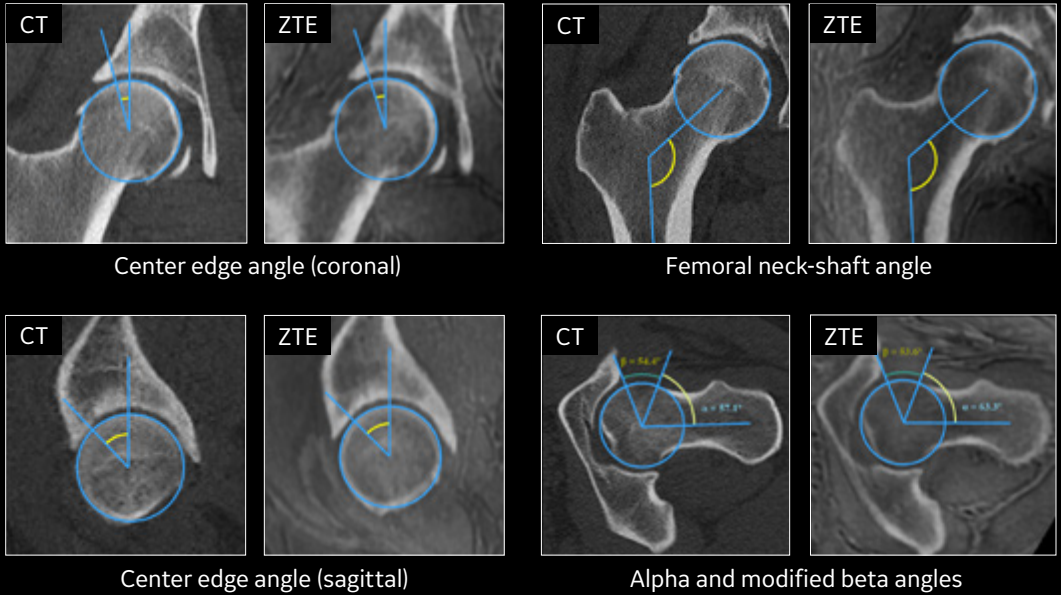


Cervical spine
1.0 x 1.0 x 1.0 mm
3:02 min.

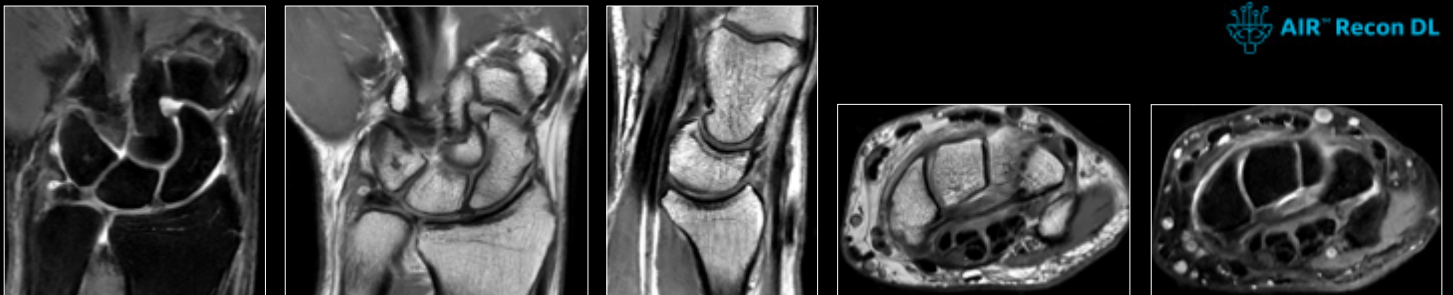

Coronal oZTEo
0.9 x 0.9 x 1.0 mm
3:14 min.

FAI Measurements



Use oZTEo with AIR™ Recon DL and AIR™ Multi-Purpose Coils



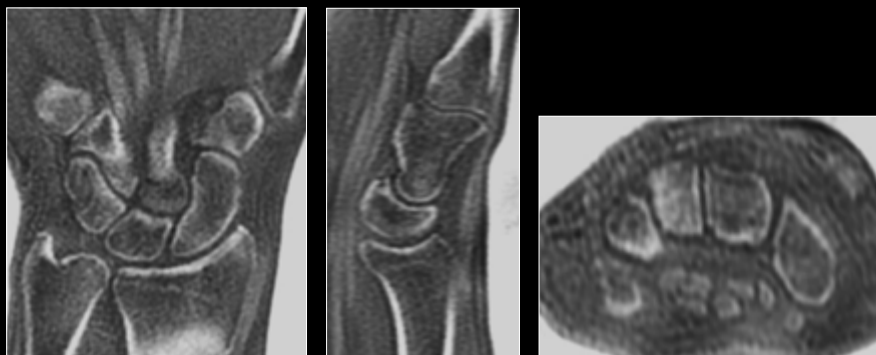
Coronal PD FatSat
0.4 x 0.6 x 2.5 mm
46 sec.

Coronal PD FSE
0.3 x 0.5 x 2.5 mm
51 sec.

Sagittal PD FSE
0.2 x 0.4 x 2.5 mm
65 sec.

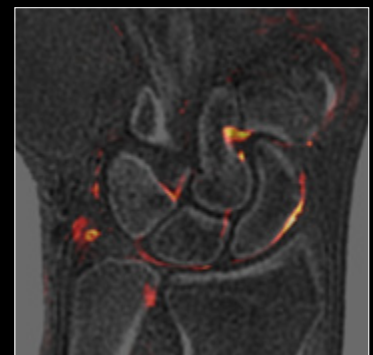Axial PD FSE
0.2 x 0.4 x 2.5 mm
57 sec.

Axial PD FatSat
0.3 x 0.5 x 2.5 mm
46 sec.



Coronal oZTEo
0.7 x 0.7 x 1.2 mm
3:09 min.

Sagittal and axial MPR



3D oZTEo fused with
Coronal PD FatSat
Integrated registration
on AW server

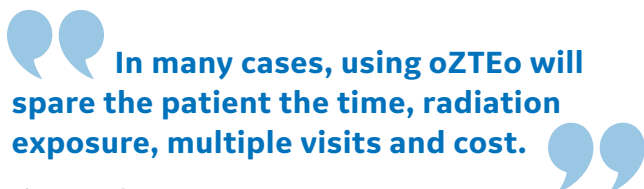
Peer-reviewed publications

Need more convincing?

See these publications on the use of oZTEo and ZTE methods for bone imaging by our GE collaborators.

Summary of the publications related to oZTEo and its research prototype precursor (as of February 2022)

Author(s)	Publication	Anatomy	No. of subjects	Key Results & Conclusion
Deslo, et al. (GE Healthcare)	J. Nucl Med 2015 https://doi.org/10.2967/jnumed.114.149997	Skull	15	Proton density-weighted ZTE imaging is an efficient means of obtaining high-resolution maps of bone tissue with sufficient anatomic accuracy for, for example, PET attenuation correction.
Argentieri, et al. (Hospital for Special Surgery)	SPINE 2017 https://doi.org/10.1097/brs.0000000000002462	Cervical Neural Foraminal Stenosis	34	Substantial agreement was found between ZTE- and CT-based grades of CNFS. Significant inter-modality differences in cervical spine curvature were found for all motion segments, except C2-3 and C3-4 (p<0.05), due to patient positioning and does not impact CNFS grade.
Breighner, et al. (Hospital for Special Surgery)	Radiology 2018 https://doi.org/10.1148/radiol.2017170906	Shoulder	34	Strong intermodality agreement between measurements and grades from CT and ZTE images.
Breighner, et al. (Hospital for Special Surgery)	AJSM 2019 http://doi.org/10.1177/0363546519878170	Hip	38 Hips from 23 patients	Significant agreement of angular measurements for hip morphology exists between ZTE MRI and CT imaging.
Cho, et al. (Gyeongsang National University Changwon Hospital)	AJNR 2019 http://dx.doi.org/10.3174/ajnr.A5916	Head Trauma - Skull	13	ZTE has diagnostic IQ comparable to CT. ZTE provides consistent results on quantitative measurement of cortical bone with CT.
Lu, et al. (Nationwide Children's Hospital)	AJNR 2019 http://dx.doi.org/10.3174/ajnr.A6175	Pediatric craniofacial Bone	14	ZTE was qualitatively comparable with CT for pre- and postoperative assessment of bony abnormalities of the skull, face, and craniocervical junction. The additional value of MR imaging was provided for brain parenchymal and soft-tissue characterization in multiple instances.
Fernandes de Mello, et al. (University California San Diego)	Arthroscopy 2020 https://doi.org/10.1016/j.arthro.2020.05.042	Shoulder Glenoid Bone Assessment	6 specimen & 10 patients	Intraclass correlation coefficients (ICCs) for inter-modality glenoid width assessment showed almost perfect agreement for both readers, ranging from 0.949 to 0.991 for the ex vivo study and from 0.955 to 0.987 for the in vivo patients.
Lee, et al. (Yonsei University College of Dentistry)	Dentomaxillofacial Radiology 2020 https://doi.org/10.1259/dmfr.20190272	TMJ	20	ZTE-MRI showed high reproducibility (k>0.80), which was comparable to that of CBCT. Flattening, osteophyte and sclerosis of the condyle and all types of bone changes in the mandibular fossa showed nearly perfect agreement between CBCT and ZTE-MRI (k = 0.80-0.90). Erosion of the condyle showed substantial agreement between both sets of images (k = 0.65-0.70).
Xu, et al. (Shanghai General Hospital)	Chinese Journal of Academic Radiology, 2020 https://doi.org/10.1007/s42058-020-00035-1	Bone destructions of bone tumors and tumor-like lesions	36	Good agreement between the two raters (K = 1, K = 0.84) in the bone destruction between CT and ZTE. CT and ZTE-MR had similar displays in lesion's boundary, periosteal reaction, bone sclerosis, bone destructions, calcifications, and soft tissues.
Sandberg, et al (Stanford University School of Medicine)	Pediatric Radiology 2021 https://doi.org/10.1007/s00247-021-05125-5	Pediatric MSK	40 (XR vs MR), 20 (CT vs MR), 25 (XR vs MR for pathology assessment)	Implementation of a diagnostic-quality ZTE MRI sequence in the pediatric population is feasible and complementary to MSK MRI studies.
Bharadwaj, et al. (University of California San Francisco)	Skeletal Radiology 2021 https://doi.org/10.1007/s00256-021-03987-2	Knee	100 (ZTE & MR) with 57 including SPGR	Diagnostic confidence in using ZTE sequences was rated "very high confidence" in 97%, 85%, 71%, and 73% of the cases for osteophytosis, subchondral cysts, fractures, and soft tissue calcifications/ossifications, respectively. In 74% of cases with osseous findings, reviewer scores indicated confidence levels (score ≥ 3) that ZTE sequences improved diagnostic certainty over standard sequences. The diagnostic confidence in using ZTE over SPGR sequences for osseous structures as well as abnormalities was favorable and statistically significant (p < 0.01).



Tiron Pechet, MD

Shields Health Care Group, Boston, MA

To learn more about oZTEo, check out our videos



[oZTEo MR Bone Imaging - Tutorial: How to perform 3D realistic volume illumination](#)



[MR Cross Talk - SIGNA™ Works AIR™ IQ Edition - oZTEo](#)

© 2022 General Electric Company - All rights reserved.

GE Healthcare reserves the right to make changes in specifications and features shown herein, or discontinue the product described at any time without notice or obligation. Contact your GE Healthcare representative for the most current information. SIGNA, GE and the GE Monogram, are trademarks of General Electric Company. GE Healthcare, a division of General Electric Company. GE Medical Systems, Inc., doing business as GE Healthcare.

JB19307XX